

# Avoiding and Managing Complications With the LDV

Tips to shorten the learning curve and increase the reproducibility of results.

BY JÉRÔME C. VRYGHEM, MD



The FEMTO LDV Femtosecond Surgical Laser (Ziemer Group AG, Port, Switzerland) is a fantastic tool that creates thin LASIK flaps safely and reproducibly. I have had the laser for 2 years, and I have participated in several of its clinical studies. Because most of the

complications that occur with the laser result from the operator's error, increased use and familiarity are the surgeon's best defense. This article suggests strategies for avoiding and managing complications with the FEMTO LDV laser.

Since its initial development, the FEMTO LDV has undergone fine-tuning that has improved its performance and lowered its rate of complications. For example, the strength of suction on the eyepiece has been increased from 500 to 700 millibars, and the eyepiece now incorporates a mechanism that compensates for a loss of suction. The FEMTO LDV's energy level has also been enhanced, which has lowered its rate of adherent flaps dramatically.

## PEARLS FOR AVOIDING COMPLICATIONS

### Examining the Device

The very first thing the surgeon or technician must do before creating a flap with the FEMTO LDV is examine the laser's head for cleanliness. Dust particles or air bubbles trapped in between the InterShield spacer (a plastic foil placed over the laser that controls the flap's thickness) and the mirror can interfere with the cut and cause corneal adhesion (Figure 1). If any debris or air bubbles are visible, the user must remove the shield and clean the window before proceeding.

The surgeon must also make sure that only one InterShield spacer is attached to the window of the laser's head and that it is not the one for the previous patient. The laser emits a warning sig-

nal to prevent surgeons from reusing a shield, but they would be wise to double-check that the shield is new before proceeding. Likewise, operating the laser with two shields attached to the head may cause a superficial cut (a mini-flap), and the cut will have to be repeated.

### Energy Levels

Before applying suction, the surgeon should consult the monitor to check the laser's energy levels, which have the potential to decrease gradually. The FEMTO LDV operates best at 100% power; otherwise, it cuts less efficiently and increases the risk of flaps adhering to the corneal bed. If the laser's energy drops, the surgeon or a technician may increase it by adjusting the mirrors of the laser's head, thus enhancing its performance.

### The Cornea

Before beginning a FEMTO LDV cut, the surgeon must make sure that the epithelium is perfectly smooth. The tissue must not be allowed to dry out due to exposure. Applying too many anesthetic drops or obtrusively measuring the eye's pachymetry before performing the cut can cause epithelial damage. The resulting surface irregularity will interfere with the laser's cut, causing adhesions, an uneven bed, and perhaps even a pseudobuttonhole.

I think it is essential to calculate the thickness of the flap

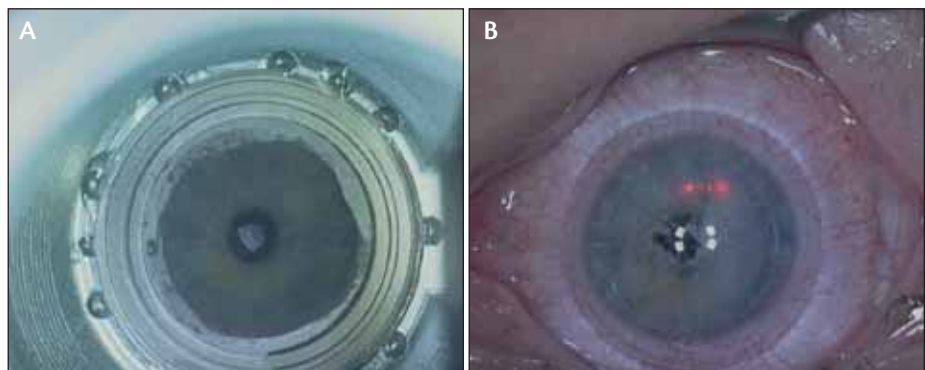
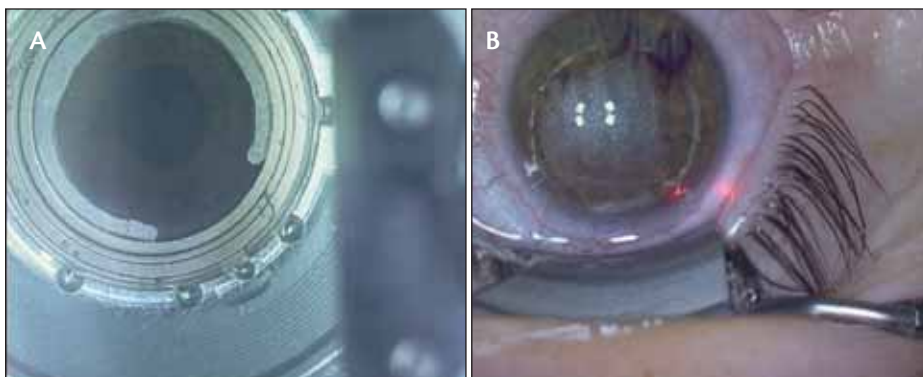
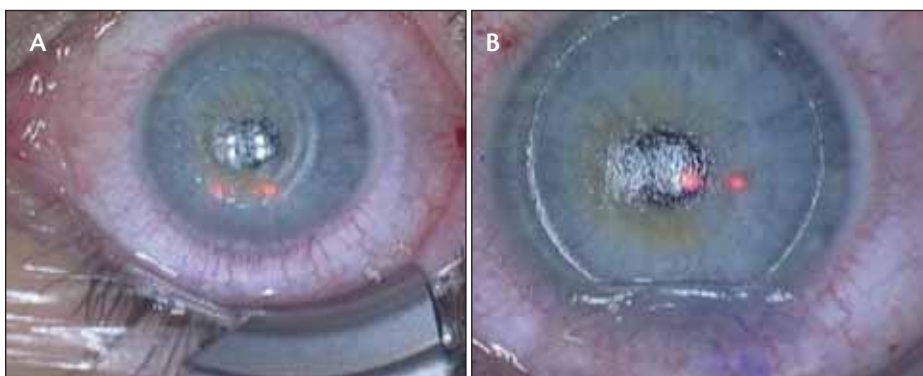


Figure 1. An air bubble trapped underneath the FEMTO LDV's foil (A) causes an area of the cornea to remain uncut after the laser's pass (B).



**Figure 2.** If the surface of appplanation does not cover 70% of the laser head's window (A), the resulting flap can be decentered and/or too small (B).



**Figure 3.** A mini-flap (A) was recut immediately and lifted without complication (B).

before starting any excimer laser treatment. I calculate the flap's intraoperative thickness using a subtraction method, in which the thickness of the cornea or bed is considered to be the lowest of at least five consecutive central corneal measurements made with a pachymeter. I favor the Corneo-Gage pachymeter (Sonogage, Inc., Cleveland, OH). I measure the corneal thickness before making the flap and determine the thickness of the stromal bed immediately after making the flap (before performing the ablation). The difference between the two measurements is the flap's thickness.

### Suction

The laser's vacuum suction ring comes in four diameters: 8.5; 9.0; 9.5; and 10.0 mm. I prefer the 9.5-mm ring for most eyes. Coating the epithelium with a viscosurgical device helps to ensure appropriate suction between the eye and the laser's head. Most FEMTO LDV users outside the United States choose Laservis viscoelastic (0.25% hyaluronate; TRB Chemedica International SA, Geneva, Switzerland [not available in the US]), because its particular viscosity promotes suction. The surgeon must apply enough of the viscoelastic to eliminate any air bubbles trapped beneath the suction

ring. If large enough, these air bubbles can block the laser beam and interrupt the cut, potentially resulting in uncut margins of the flap.

Obtaining sufficient appplanation and maintaining strong suction between the handpiece and the eye are critical to achieving a successfully cut flap. Users of the FEMTO LDV can verify that the suction is complete by making sure that the surface of appplanation fills at least 70% of the window on the laser's head (Figure 2). Suction is difficult to achieve in certain eyes. Because the LDV's handpiece is asymmetrical, positioning it over left eyes and deep-set eyes can be challenging, and the surgeon may have to tilt the patient's head to the right (this positioning is called the *temporal canvas*).

Once suction has been established, the surgeon does not need to lift the eye with the laser's handpiece to verify the suction, as ophthalmologists sometimes do with manual microkeratomes. Because the strength of the LDV's suction is slightly lower than that of a mechanical microkeratome (700 millibars for the former compared with 800 to 850 millibars for the latter), lifting the eye in this manner may disengage the suction.

### Centration

There are a few steps that surgeons may follow to maximize the flap's centration with the FEMTO LDV. Primarily, I use minimal magnification on the excimer laser's microscope when positioning the laser's head over the eye. I find that setting the microscope to 1.0 magnification gives me a better view of the entire field.

Second, the surgeon must make sure the eye is positioned correctly before he applies the suction ring. There should be an equal amount of space between the eyelid and the limbus superiorly and inferiorly. Lifting the patient's chin can help achieve the desired position. With deep-set eyes, the surgeon may need to ask the patient to look in a specific direction to aid centration.

### EXPERIMENTING WITH THE FLAP'S THICKNESS

The FEMTO LDV femtosecond surgical laser (Ziemer Group AG, Port, Switzerland) has the ability to create flaps of 140, 110, 100, 90, and even 80  $\mu\text{m}$  with a very low standard of deviation (approximately 10  $\mu\text{m}$ ). Although my standard flap is 100  $\mu\text{m}$  when I use the 110- $\mu\text{m}$  InterShield spacer, I have conducted several clinical studies in which I created ultra-thin flaps (90 and 80  $\mu\text{m}$ ) with the LDV laser. The 90- $\mu\text{m}$  InterShield spacer is very useful for thin corneas and eyes with high ametropia in patients who desire LASIK. I have cut 90- $\mu\text{m}$  flaps in 110 eyes since the beginning of this year, and the only complication I experienced was a flap's tearing in its periphery due to corneal adhesion, which I attributed to low energy levels. Still, I recommend using 90- $\mu\text{m}$  flaps only when necessary.

Based on my clinical study in 33 eyes, I think 80- $\mu\text{m}$  flaps are too thin to work with safely. They wrinkle too easily when moved. I had to use bandage contact lenses over these eyes in the early post-LASIK period to make sure the flaps did not develop folds. Also, I found that the stromal bed appeared rough, almost like cobblestones, due to the higher density of the superficial stroma (the effect has no visual impact, however). In one eye, air bubbles developed within the flap and caused underlying adhesions. One eye developed a pseudobuttonhole due to a dry spot on the epithelium. Moderate haze developed in the interface of four eyes and resulted in a slight loss of BCVA.

Third, to assist the surgeon in obtaining centration, the manufacturer has engraved a black ring within the laser's head. However, I do not feel that this ring works effectively, because it is quite defocused when viewed through a microscope. I have asked the company to improve this feature or else find another way to ensure good centration.

#### Size of the Flap

I find that the best parameters for most eyes are flaps of 9.5 mm in diameter with a hinge that is 0.4 mm wide. Ten-millimeter flaps are too large; they run the risk of cutting the blood vessels of the peripheral cornea and causing bleeding. Also, the laser cannot cut through the limbus if a flap's diameter happens to traverse it, and the laser will leave an uncut margin. In hyperopic or astigmatic eyes, I find that a

9.5-mm optical zone leaves plenty of corneal tissue for the ablation.

#### Alignment

Although it is necessary to apply corneal markings before making a flap with a microkeratome, the dye will absorb the FEMTO LDV's laser beam and may interfere with the laser's cut. Therefore, LDV users must mark the cornea after performing the ablation. Marking the cornea after the cut allows a better realignment of the flap after the ablation, particularly in the rare cases in which a free flap occurs. I use a hockey stick (Moria, Antony, France) for corneal marking.

#### Adhesions

Occasionally, the FEMTO LDV will make flaps that adhere to the corneal bed and do not lift easily. Moderate adhesions are detached fairly easily by any variety of spatula (for example, the Vryghem spatula 19087 (Moria) or the Storz Manipulator E 9071 (Bausch & Lomb, Rochester, NY). Stronger adhesions may require a small hook with a sharp point to separate the tissue. If an adhesion is too strong to lift, the surgeon must recut the flap. The LDV's software permits recuts within 5 minutes of the initial cut (Figure 3). The surgeon may use the same flap parameters, but he must apply the excimer laser treatment within a smaller optical zone. Also, surgeons need to remember to change the laser's trajectory if they are recutting only a portion of the flap, and they must eliminate the flap's margins to accommodate the smaller optical zone. Otherwise, there will be a flap within a flap.

#### SUMMARY

Compared with the flap-cutting outcomes of available mechanical microkeratomers, the FEMTO LDV laser produces thinner flaps and a flap thickness that is more predictable. Other parameters, such as the width of the flap's hinge, are also more predictable, thus allowing the surgeon more control of the cut. Like any surgical device, the FEMTO LDV involves a learning curve. Surgeons quickly learn to operate it with minimal problems, however, and most complications are easily corrected, as I have described. In cutting thinner flaps, the surgeon preserves more corneal tissue, farther away from the 250- $\mu\text{m}$  ectasia barrier. This makes the flap procedure safer and enables surgeons to treat higher degrees of ametropia. ■

*Jérôme C. Vryghem, MD, is with the Brussels Eye Doctors in Belgium, and he is a member of the Cataract & Refractive Surgery Today Europe Editorial Board. He acknowledged no financial interest in the products or companies mentioned herein. Dr. Vryghem may be reached at +32 2 741 69 99; j.c.vryghem@vryghem.be.*